

*NST II Psychology*

*NST II Neuroscience (Module 5)*

# Brain Mechanisms of Memory and Cognition – 2

## Motion processing; spatial cognition; parietal cortex

**Rudolf Cardinal**

Department of Experimental Psychology

*Monday 12, 19, 26 Jan; 2, 9, 23 Feb 2004; 10 am*

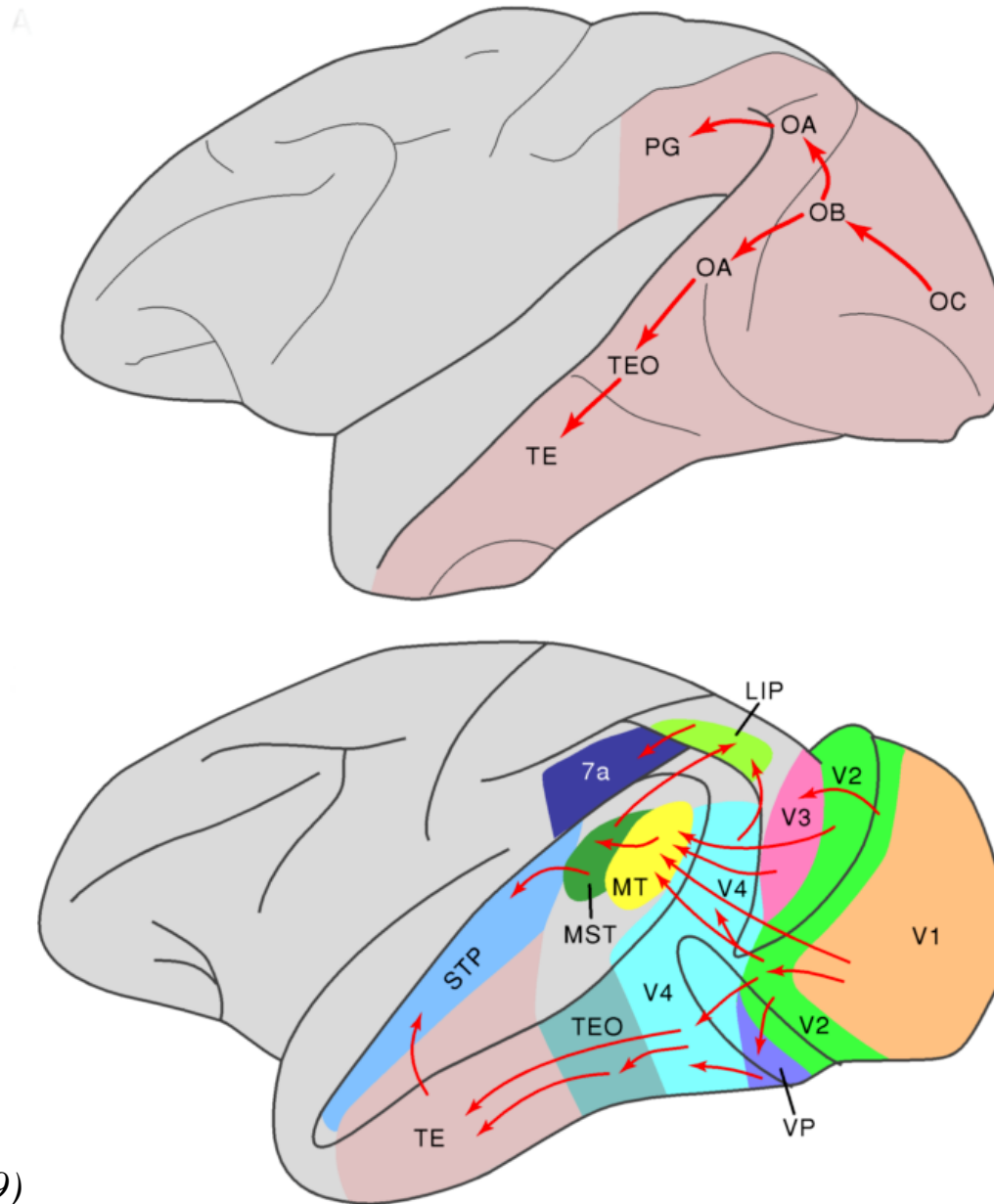
*Physiology Main Lecture Theatre*

*Slides will be at [pobox.com/~rudolf/psychology](http://pobox.com/~rudolf/psychology)*



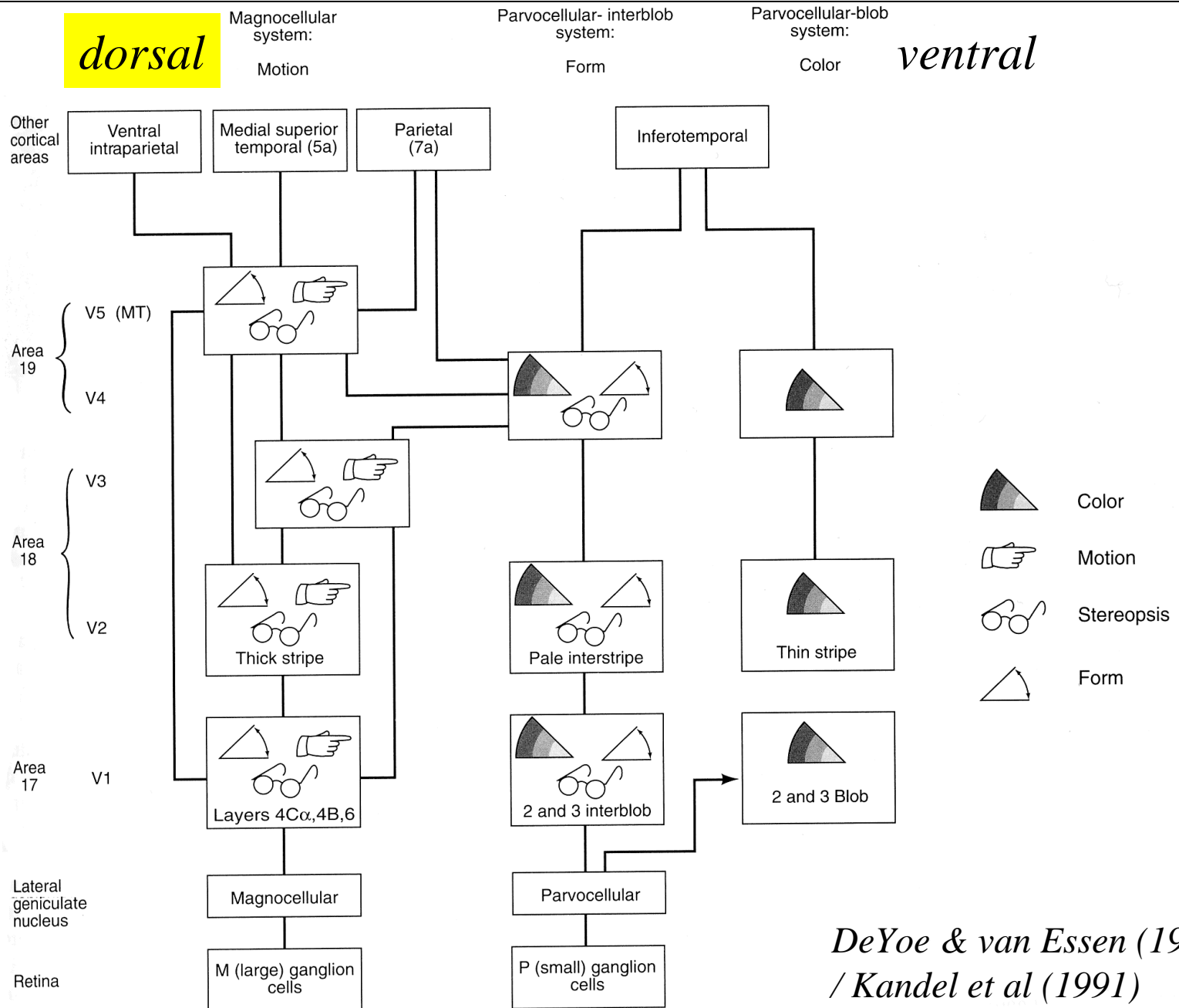
# Two visual streams

---



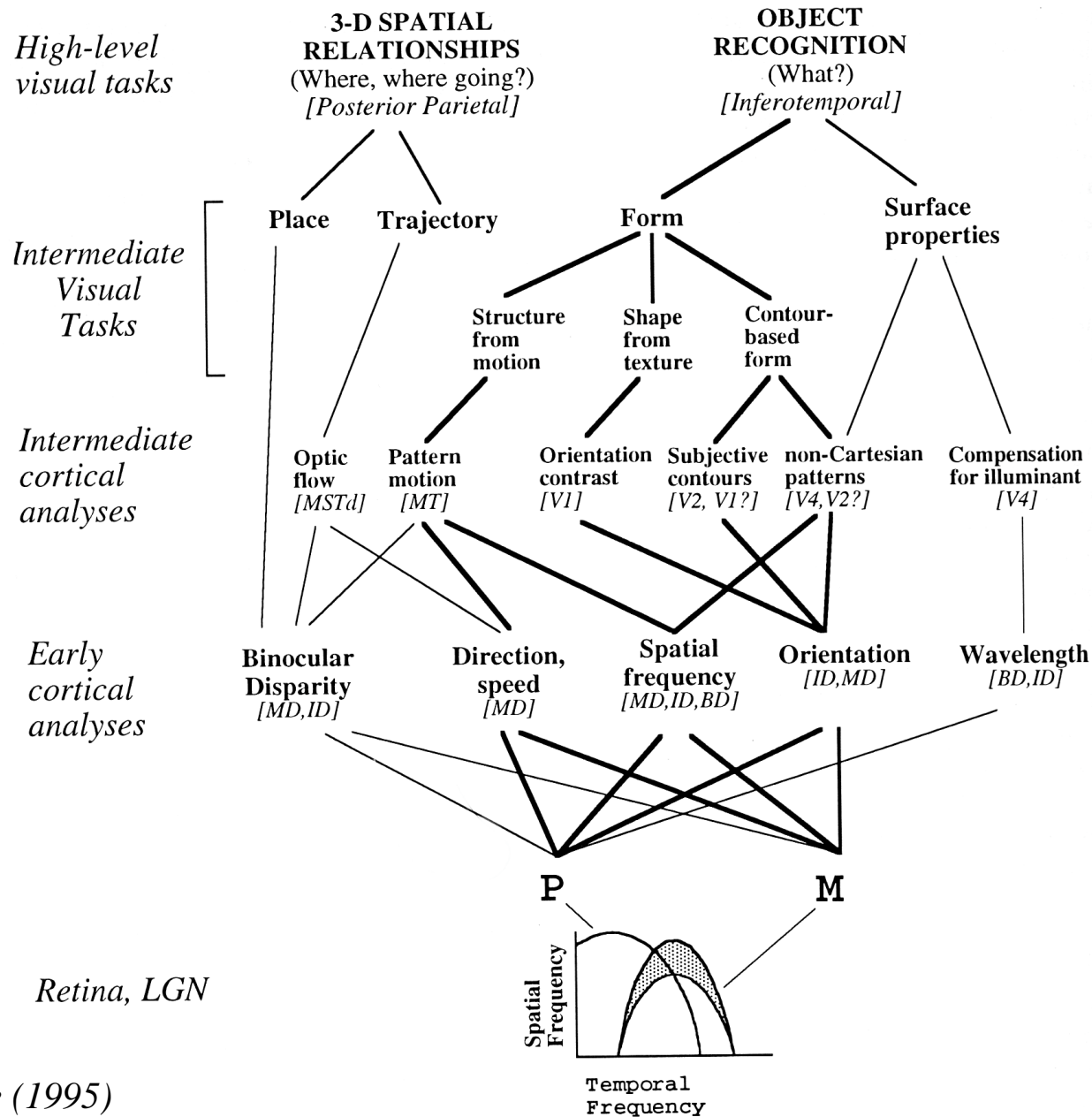
*from Zigmond et al (1999)*

# Concurrent (parallel) processing begins at the retina





*DeYoe & van Essen (1988)  
/ Kandel et al (1991)*

# Information flow in the visual streams




# Colour (V4) and motion (V5)

*colour (versus monochrome)*



*moving dot image (versus still)*

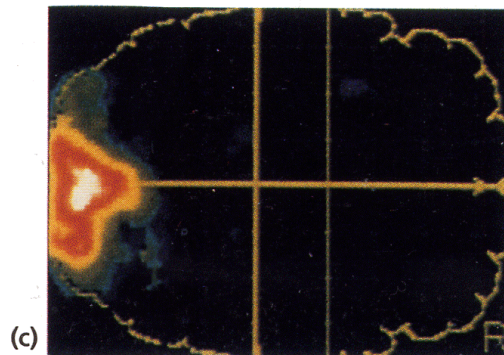


(a)

V4

(b)

V5



(c)

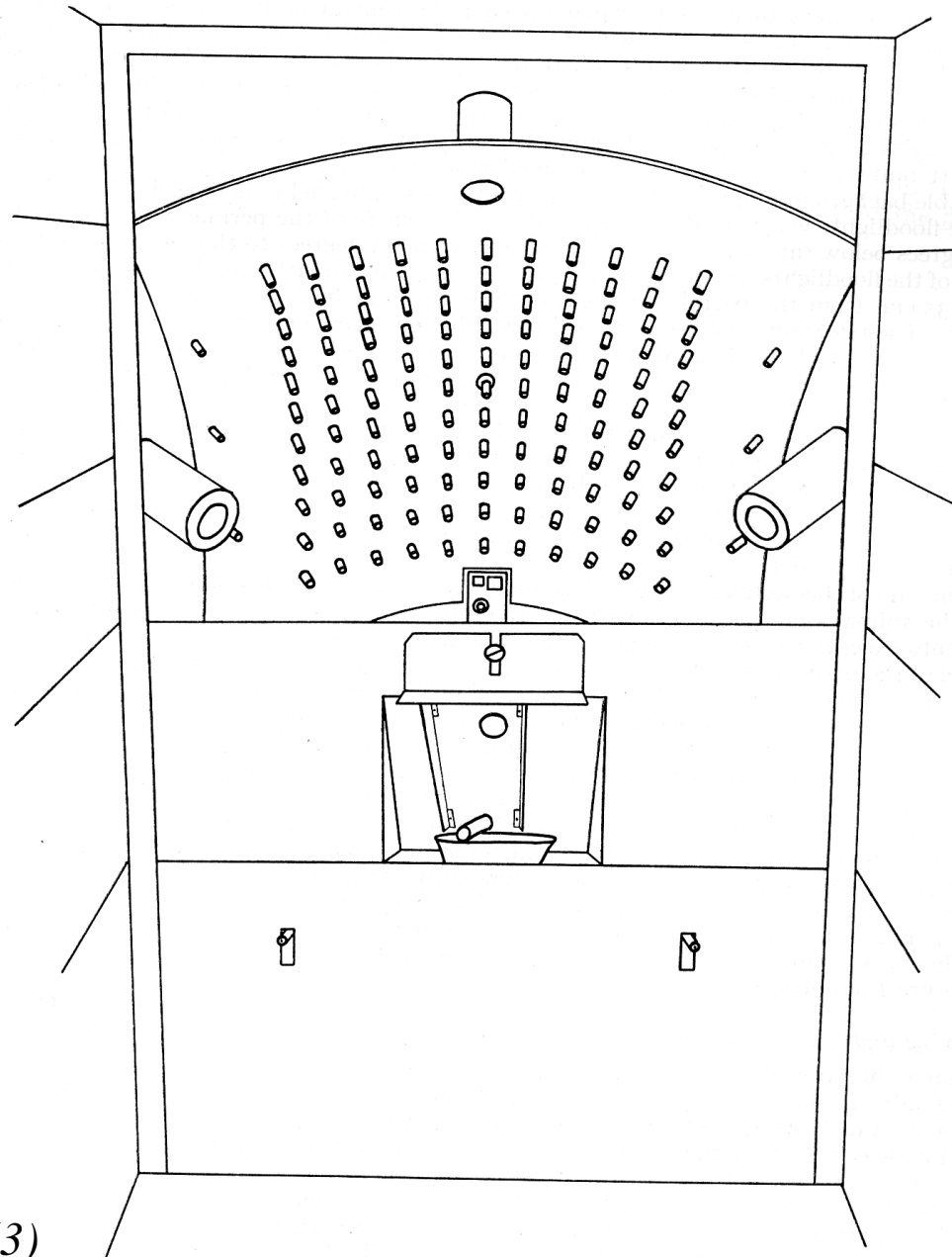
*V1/V2 active in all conditions*

*Blindsight:  
residual visual function  
after V1 lesions*

# Blindsight: detection of visual stimuli without perception


---

*Perimeter, for measuring visual fields in monkeys*



*Cowey & Weiskrantz (1963)*

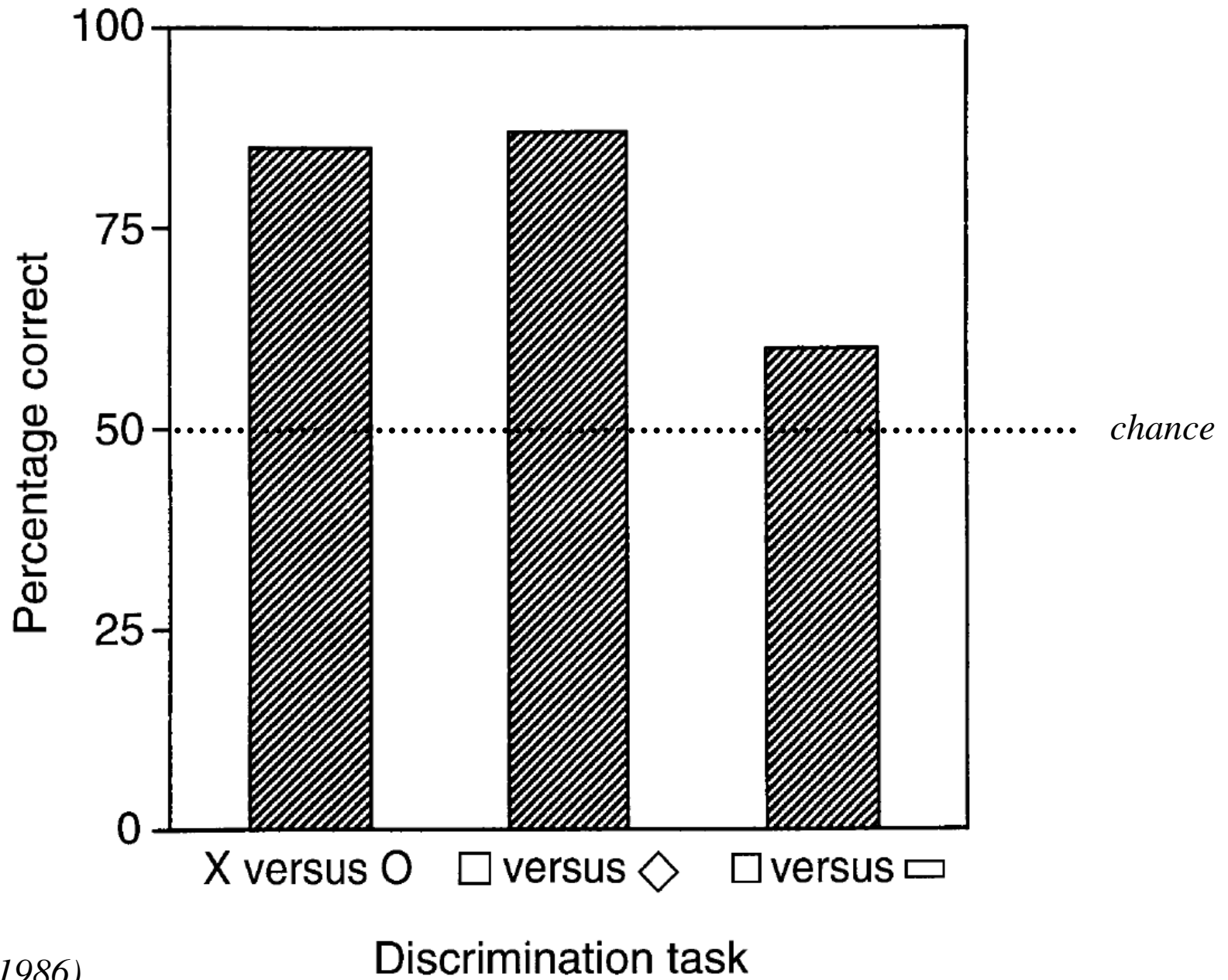
## Blindsight: Helen



**Fig. 15** The bilaterally destriated monkey Helen roamed freely among the objects in the test arena. She would, however, bump into the obstacle made of transparent perspex, as shown, revealing that her navigation was not based on non-visual cues. (Photographs taken from a film by N. Humphrey, and published with his kind permission.)

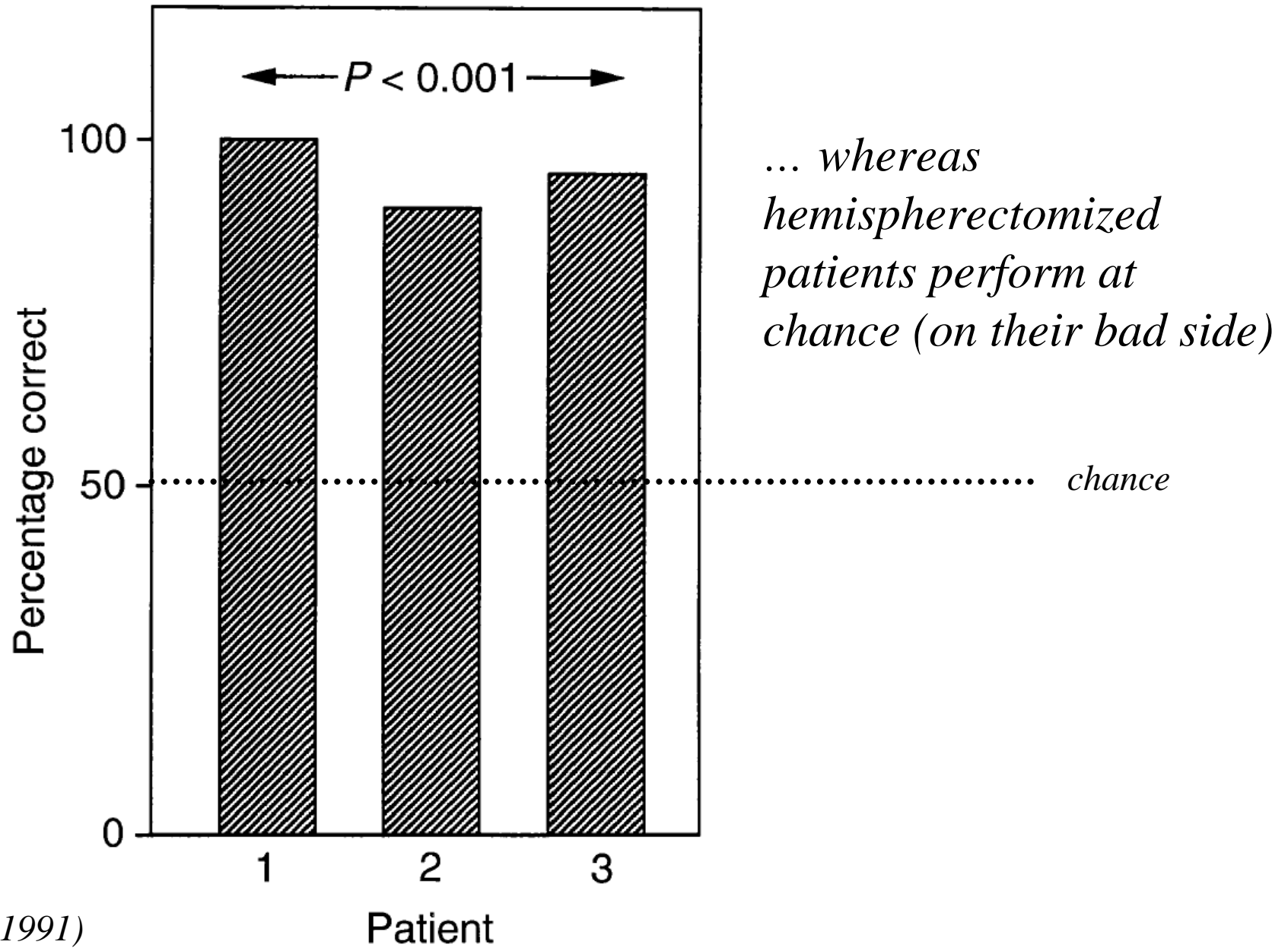


# Blindsight: patient D.B. in a forced-choice discrimination



Weiskrantz (1986)

# Blindsight: motion discrimination following V1 lesions

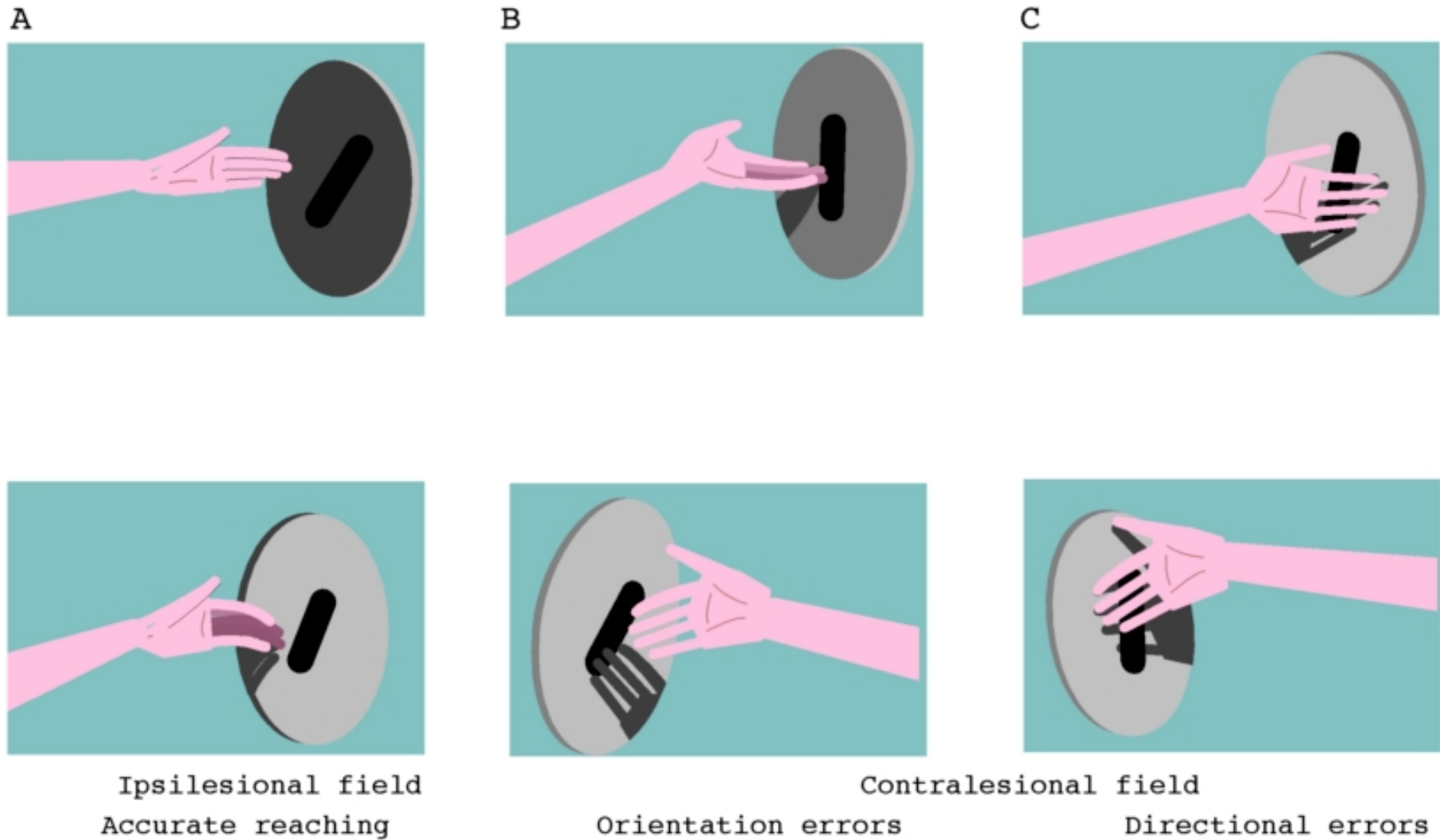


*Perenin (1991)*

*Effects of parietal cortex lesions.  
Bálint's syndrome; neglect*

# Optic ataxia: impaired visual guidance of movement

---



*figure from Zigmond et al. (1999)*

# Simultanagnosia

---

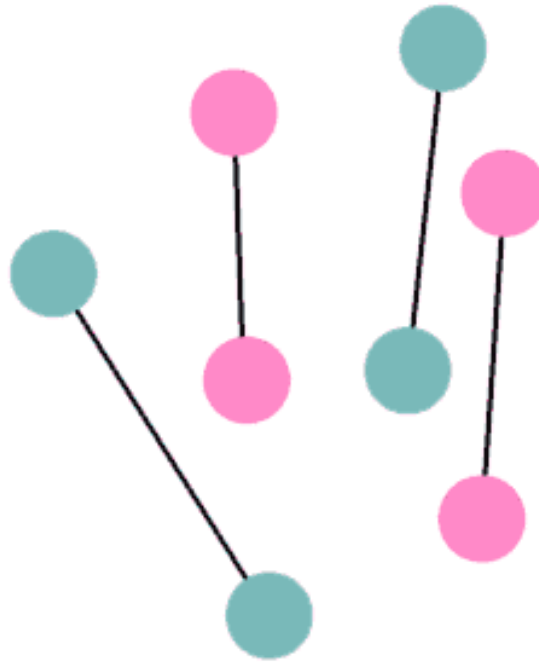
*'Are there circles of two different colours?'*

Random



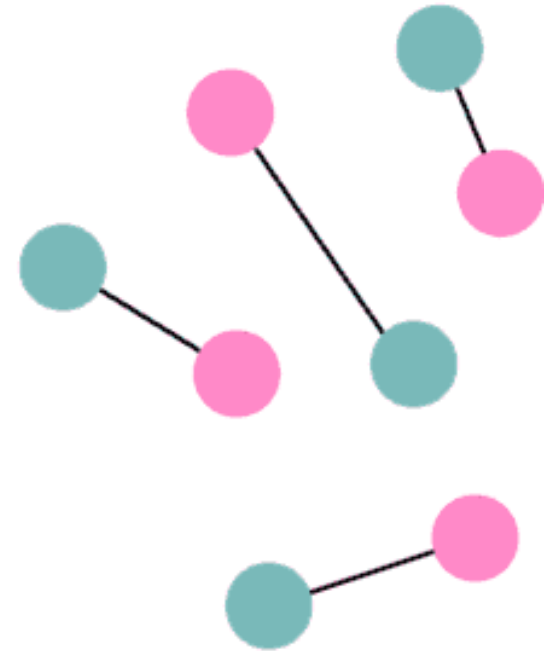
*'No.'*

Single



*'No.'*

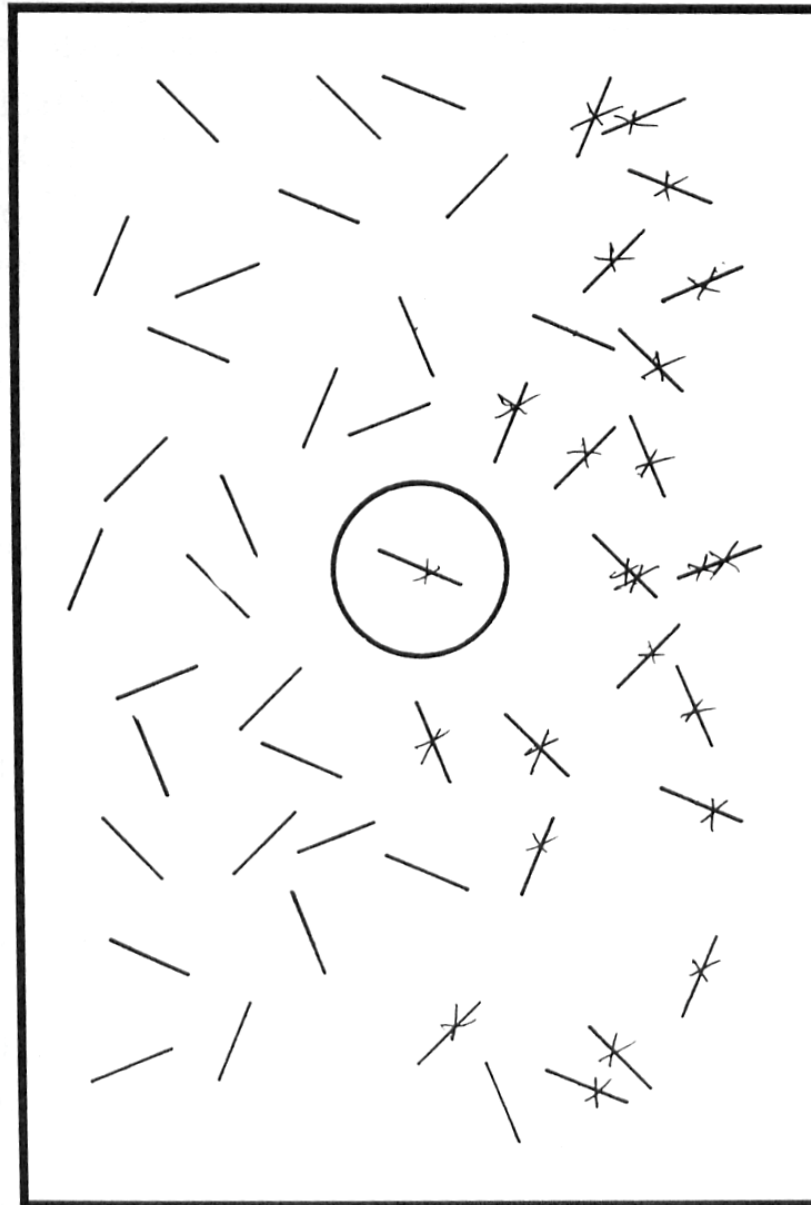
Mixed



*'Yes.'*

# Neglect: line cancellation task


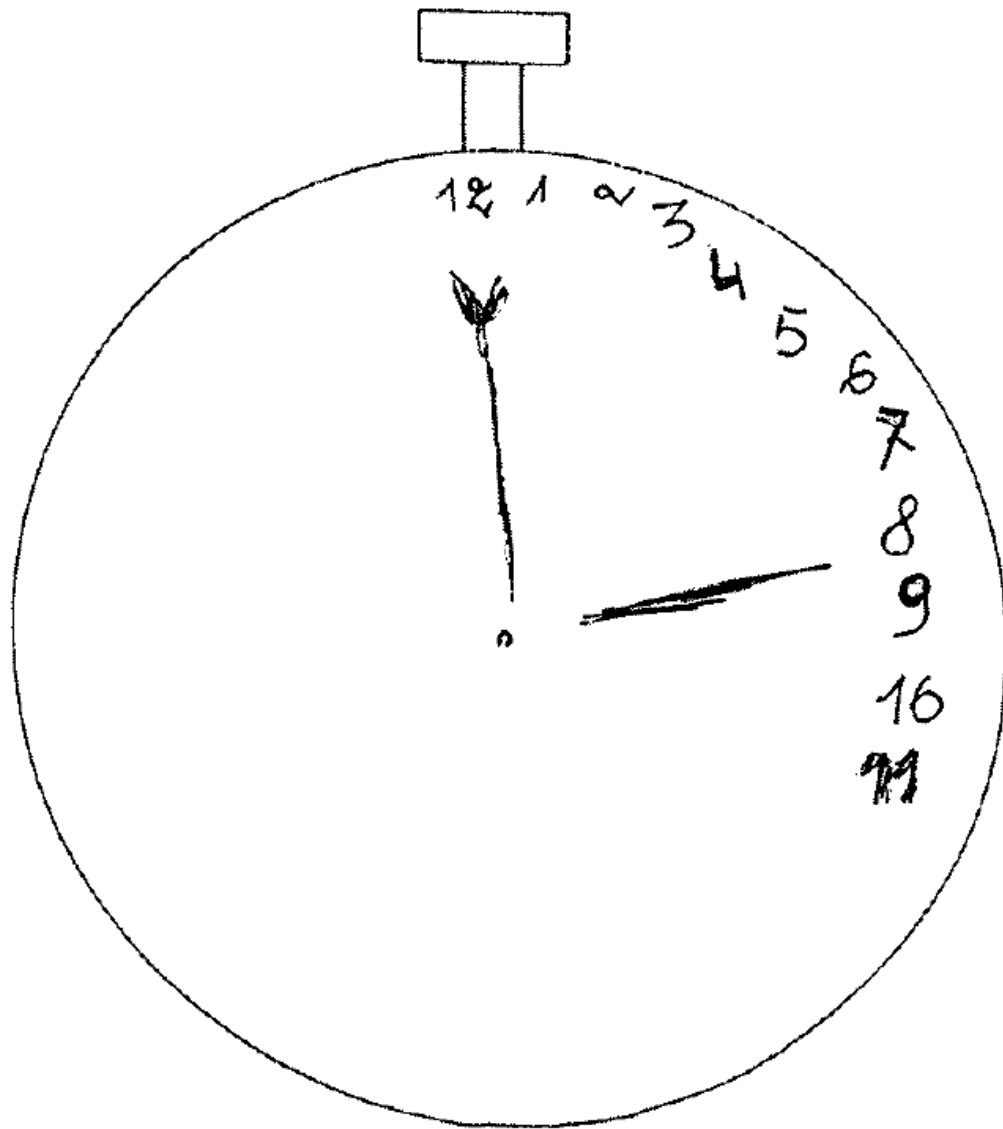
---



*Kartsounis & Warrington, 1989*

# Neglect: drawings from memory


---



*Beschin et al. (2000)*

## Sensory extinction following partial recovery from neglect

---



*from Rafal & Robertson (1995)*



## Neglect is attentional: the Piazza del Duomo, Milan (1)

---



*Bisiach & Luzzatti (1978)*

## Neglect is attentional: the Piazza del Duomo, Milan (2)


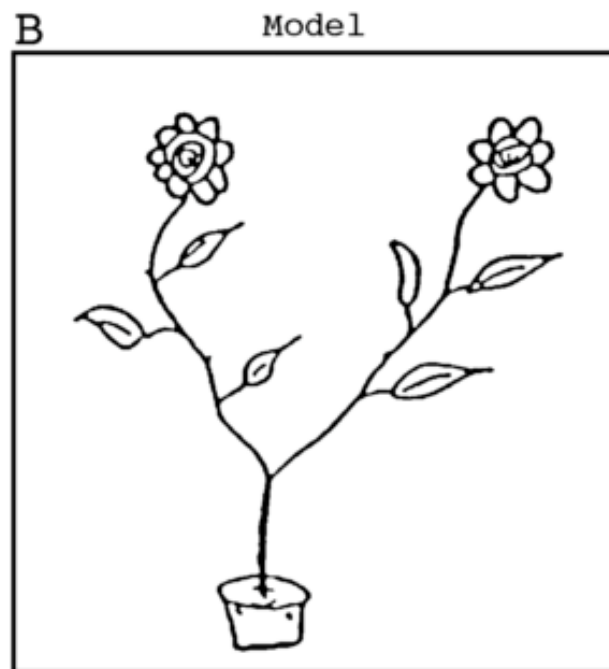

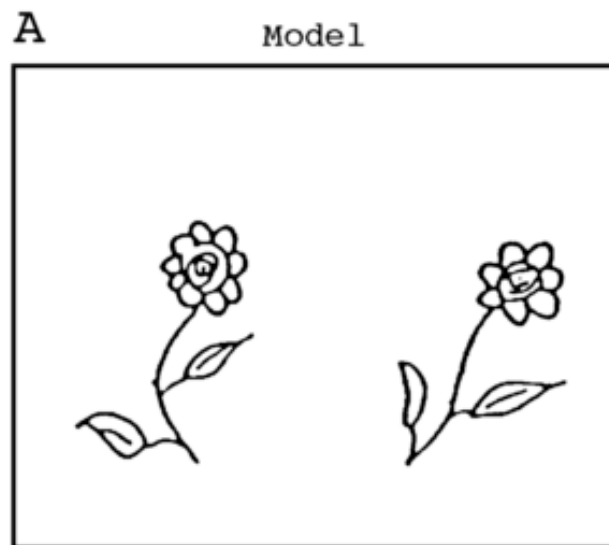
---



*Bisiach & Luzzatti (1978)*

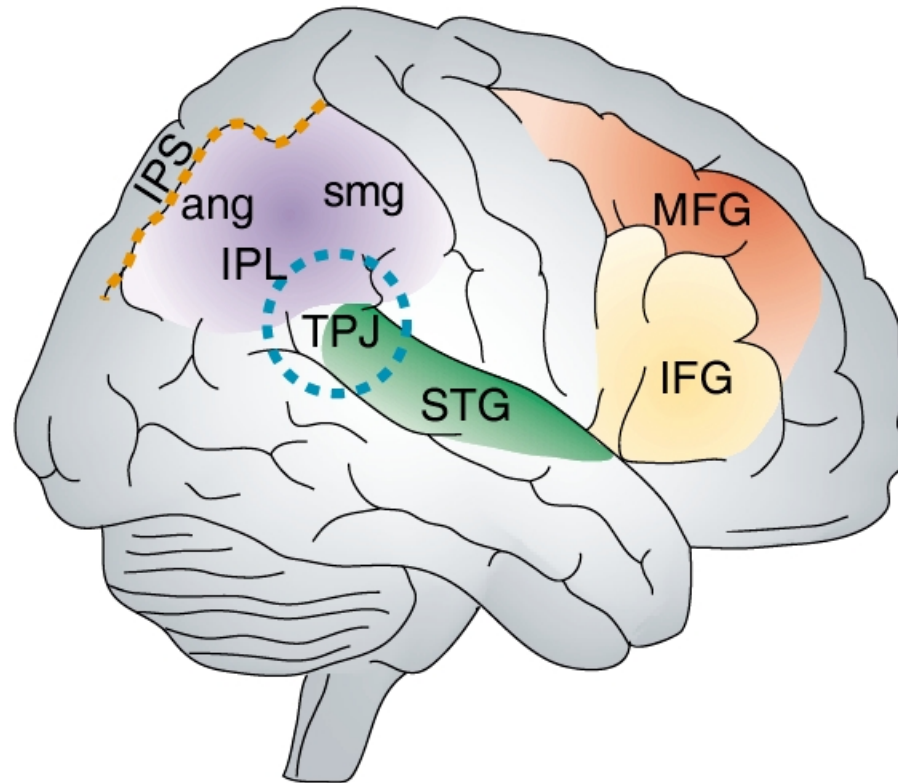
# Object-centred neglect

---



# Cortical regions damaged in neglect

---



TPJ = temporo-parietal junction

IPL = inferior parietal lobule (ang = angular gyrus; smg = supramarginal gyrus)

IPS = intraparietal sulcus

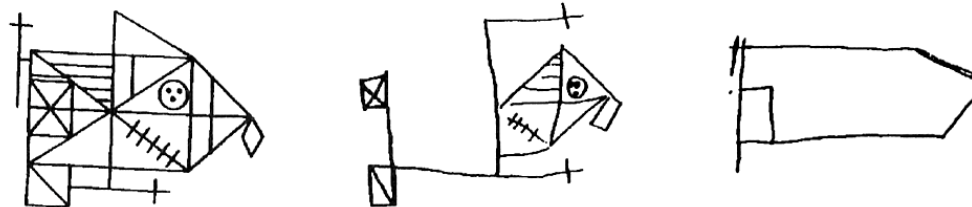

STG = superior temporal gyrus

MFG = middle frontal gyrus

IFG = inferior frontal gyrus

# Left/right asymmetry of function in the TPJ

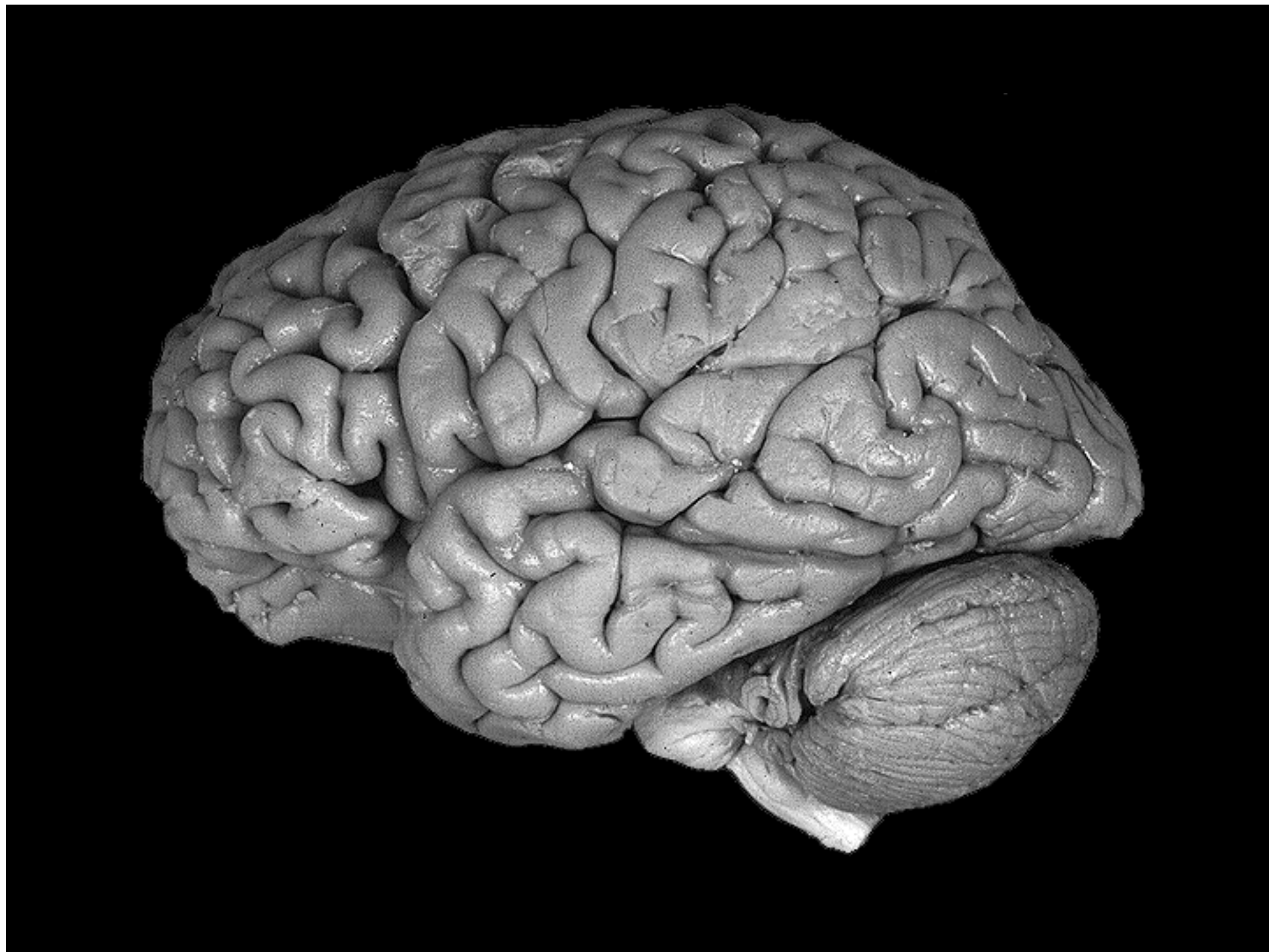
Stimulus                      Right Damage                      Left Damage



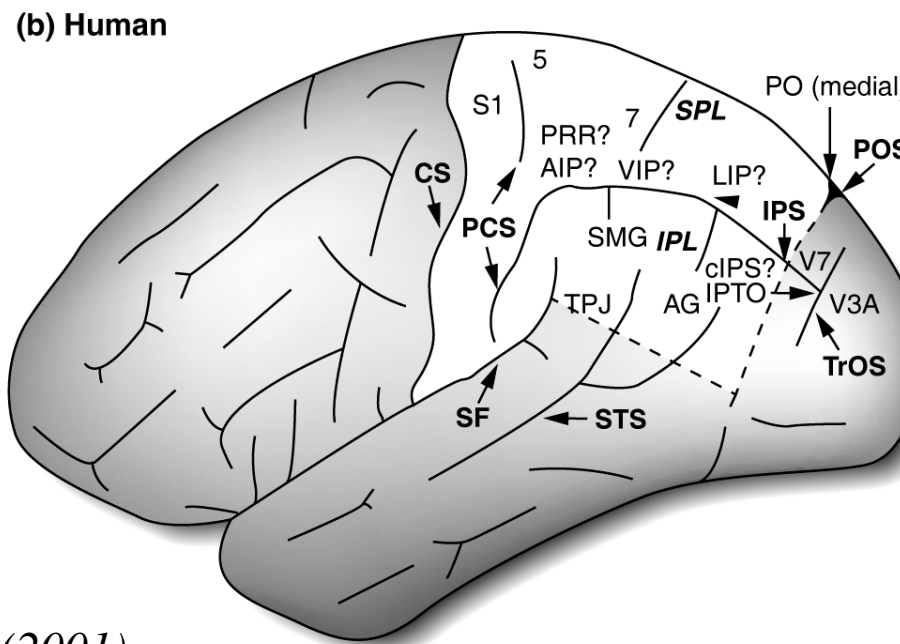
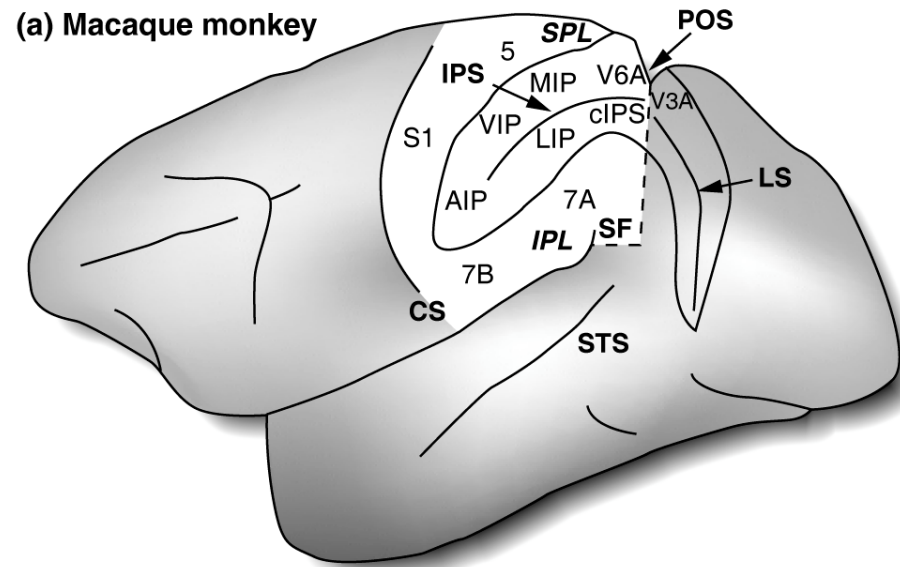
*Rey-Osterreith figure*

FIGURE 44.9 Examples of drawings of a stimulus by patients with left or right hemisphere damage. (Adapted from Robertson and Lamb, 1991.)

*Parietal cortex:  
anatomy and electrophysiology*




# Parietal cortex (with the intraparietal sulcus 'unfolded')





# A 3D world from a 2D retinal image

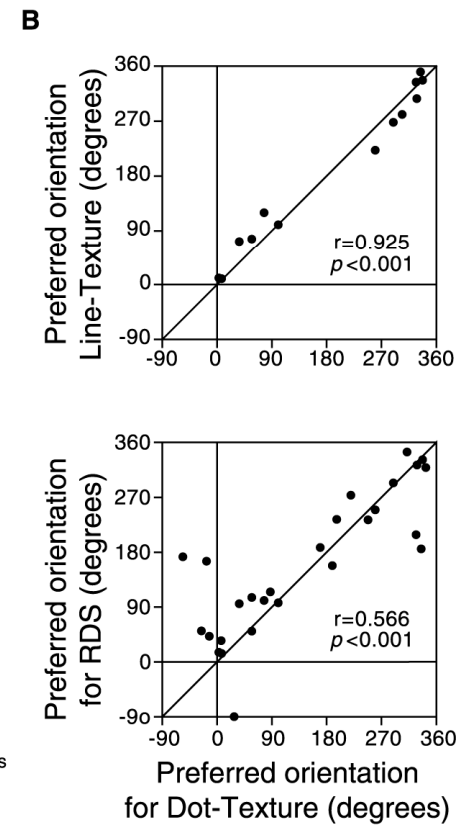
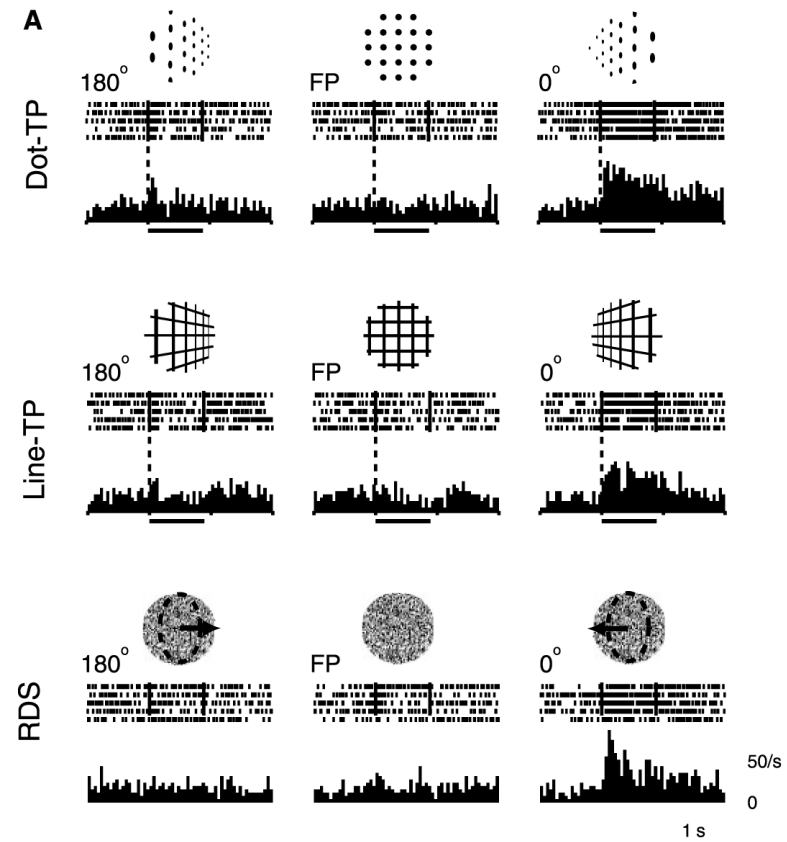

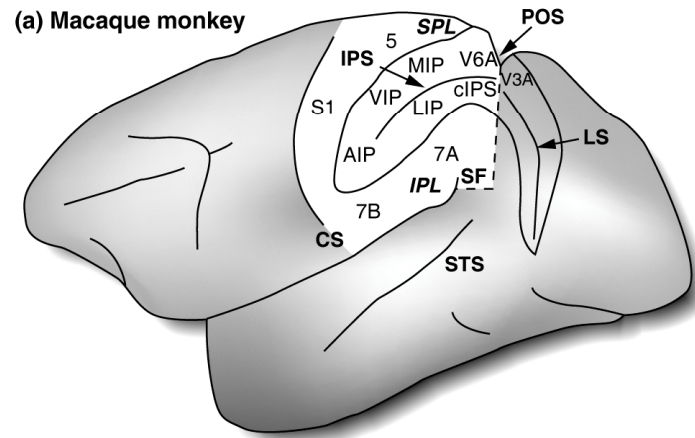
---



*There are multiple monocular cues for depth, such as texture gradient, in addition to stereopsis (binocular disparity and convergence information).*

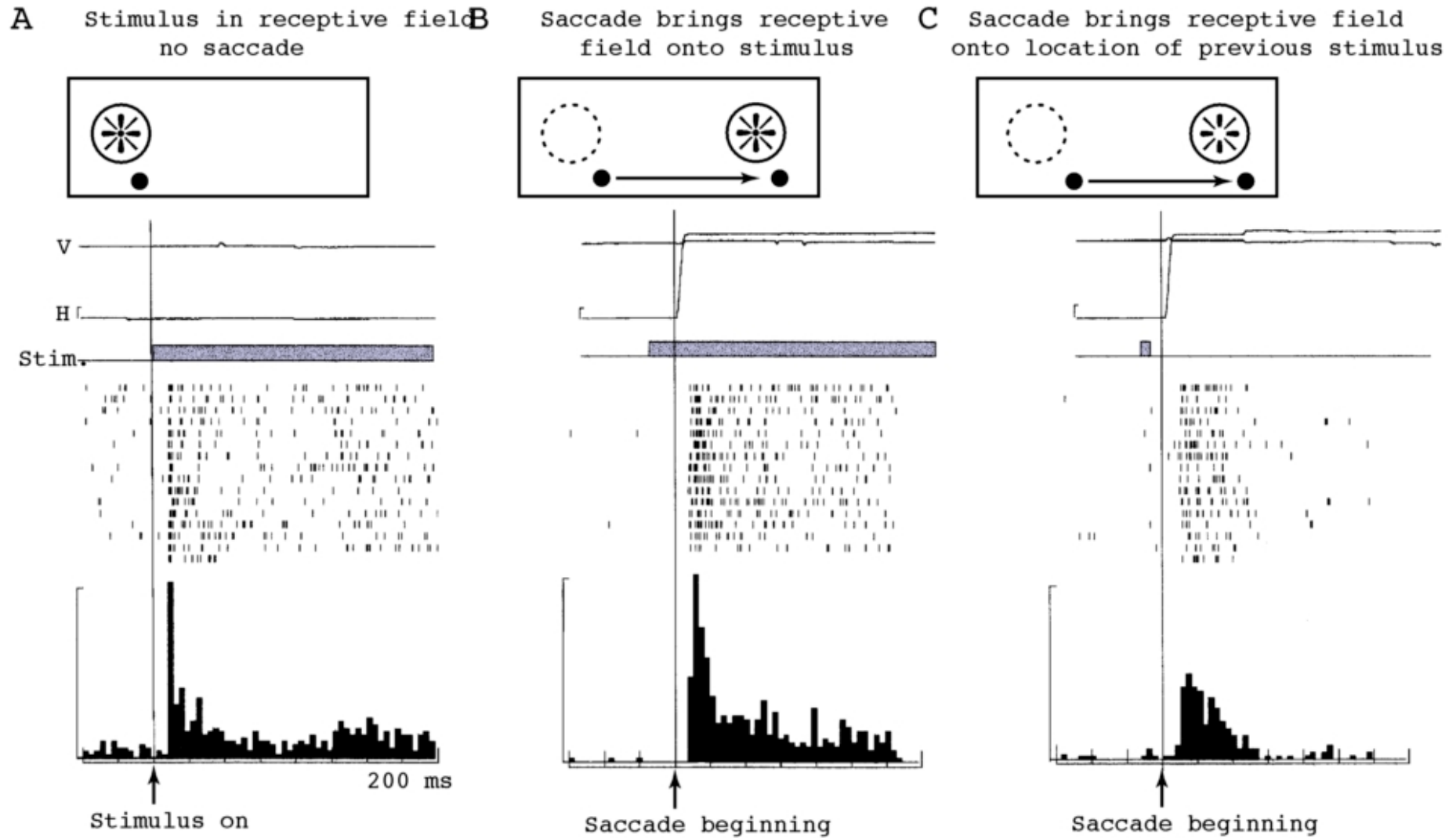
*(Above: stereo pair of satellite images. Left: 'Rue de Paris, temps de pluie' by Gustave Caillebotte, 1877.)*

# Caudal intraparietal sulcus (cIPS) and 3D spatial processing

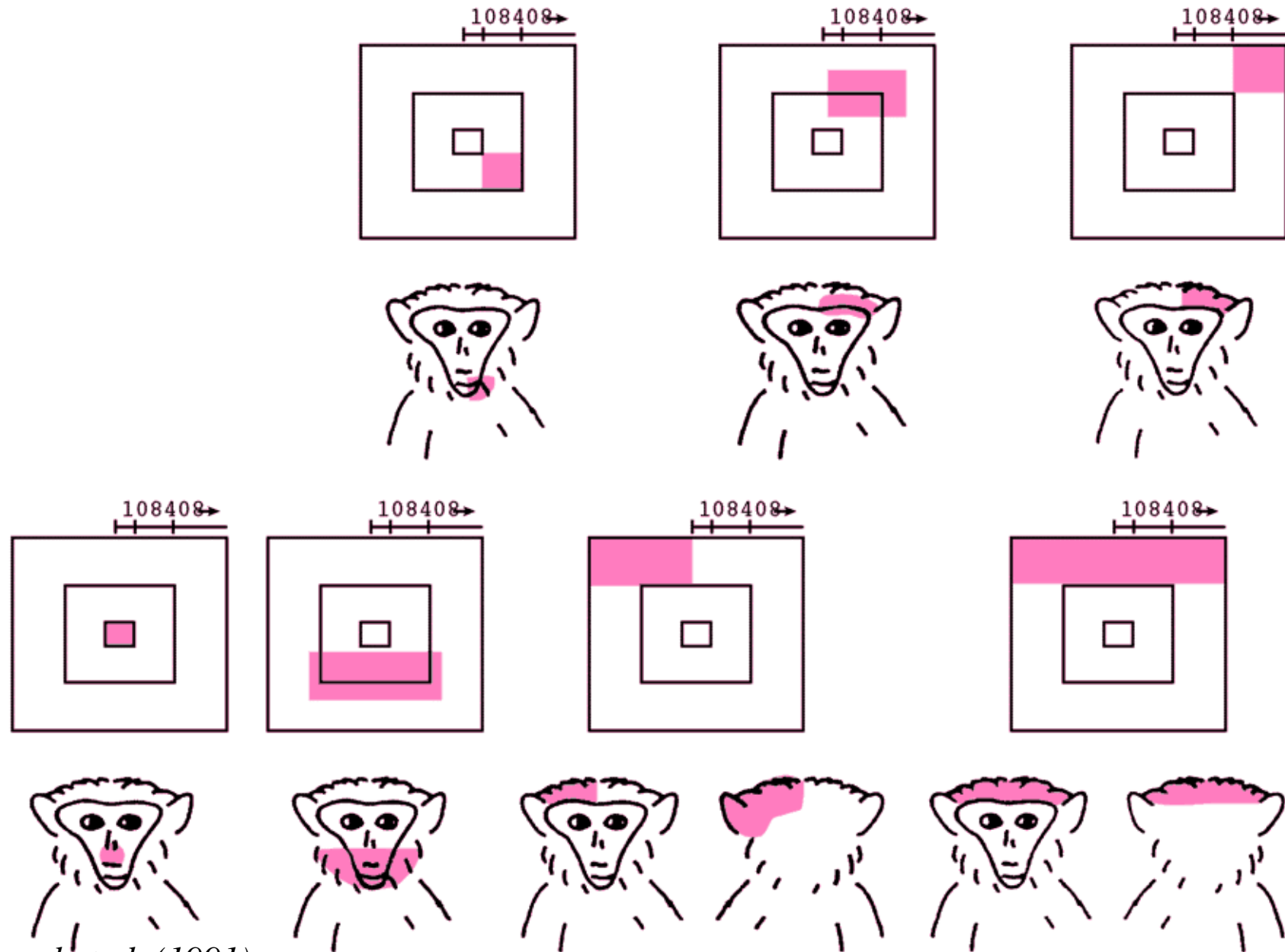


*Tsutsui et al. (2002)*  
*Science 298: 409*

# LIP neuronal responses: updated based on planned motor acts



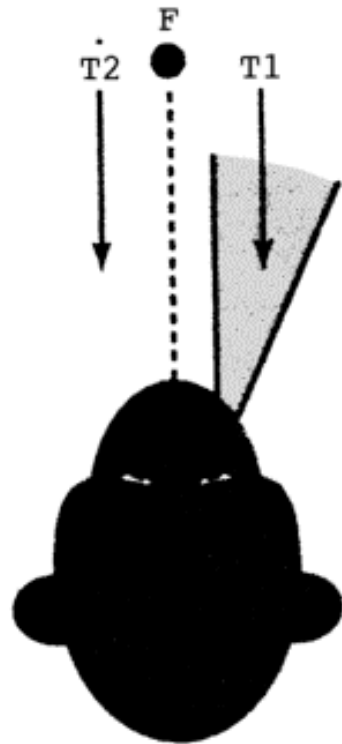
# VIP neuronal responses: polymodal, 'head-centred'



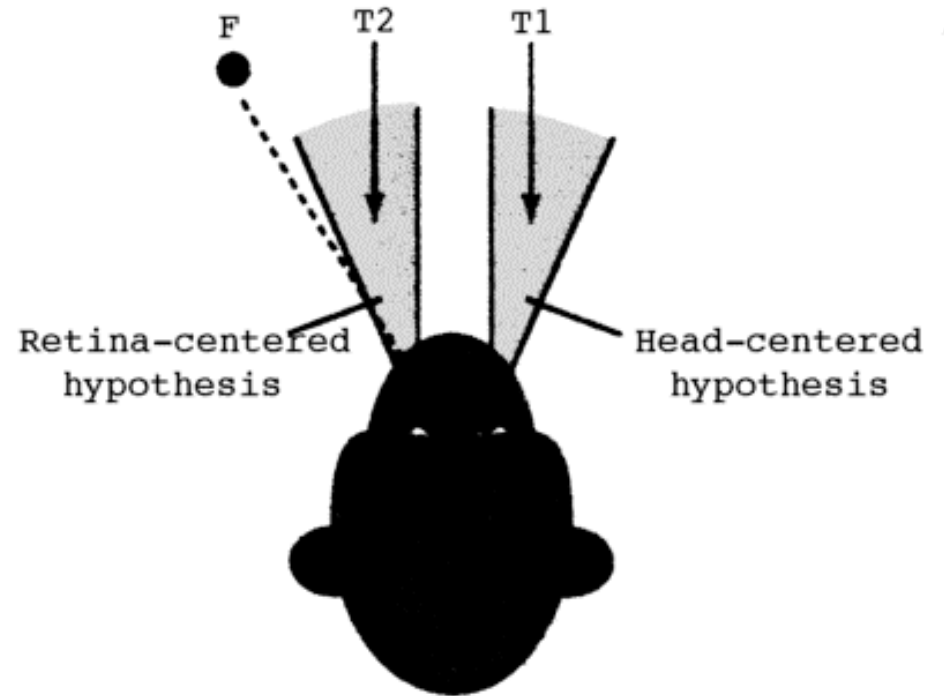
*Duhamel et al. (1991)*

# 'Head-centred' receptive fields in VIP

---



*monkey looking  
straight ahead (at F);  
grey = receptive field*



*monkey looking  
30° to left (at F)*

## Electrophysiology - 7a, 7b, AIP: visuomotor control

---

- **7a:** Similar to LIP. Visual receptive fields; also respond to position of eyes in orbits; thus may e.g. respond best to stimulus in RF when eye in a certain position.
- **7a:** Activity related to saccades, visual pursuit, and also movement of arm towards a target (N.B. relevance to optic ataxia) and manipulation of an object. *Visuomotor.*
- **7b:** Response to somatosensory as well as visual input.
- **AIP:** involved in visual guidance of precise hand movements. *Visuomotor.* Receives info about 3D properties of objects from other parietal regions. Active during all phases of grasping activity.

## Electrophysiology - 5: somatomotor control ('active touch')?

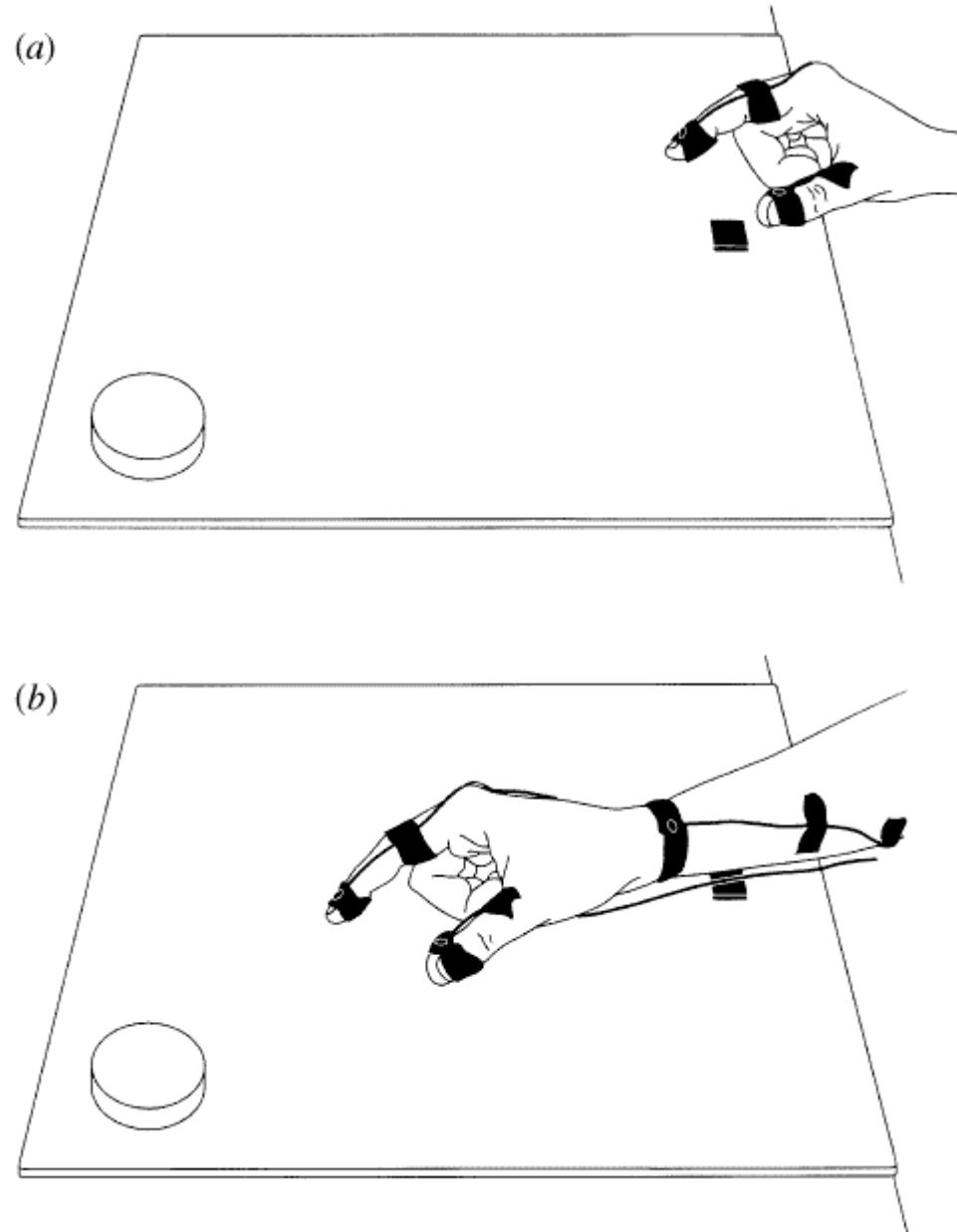
---

- **5:** Predominantly somatosensory and proprioceptive input (N.B. is adjacent to primary somatosensory cortex). Responds e.g. to active touching, but not to passive visual or cutaneous stimulation.

*The dorsal stream:  
visuomotor control*

# Perception of object size *versus* grasping

---

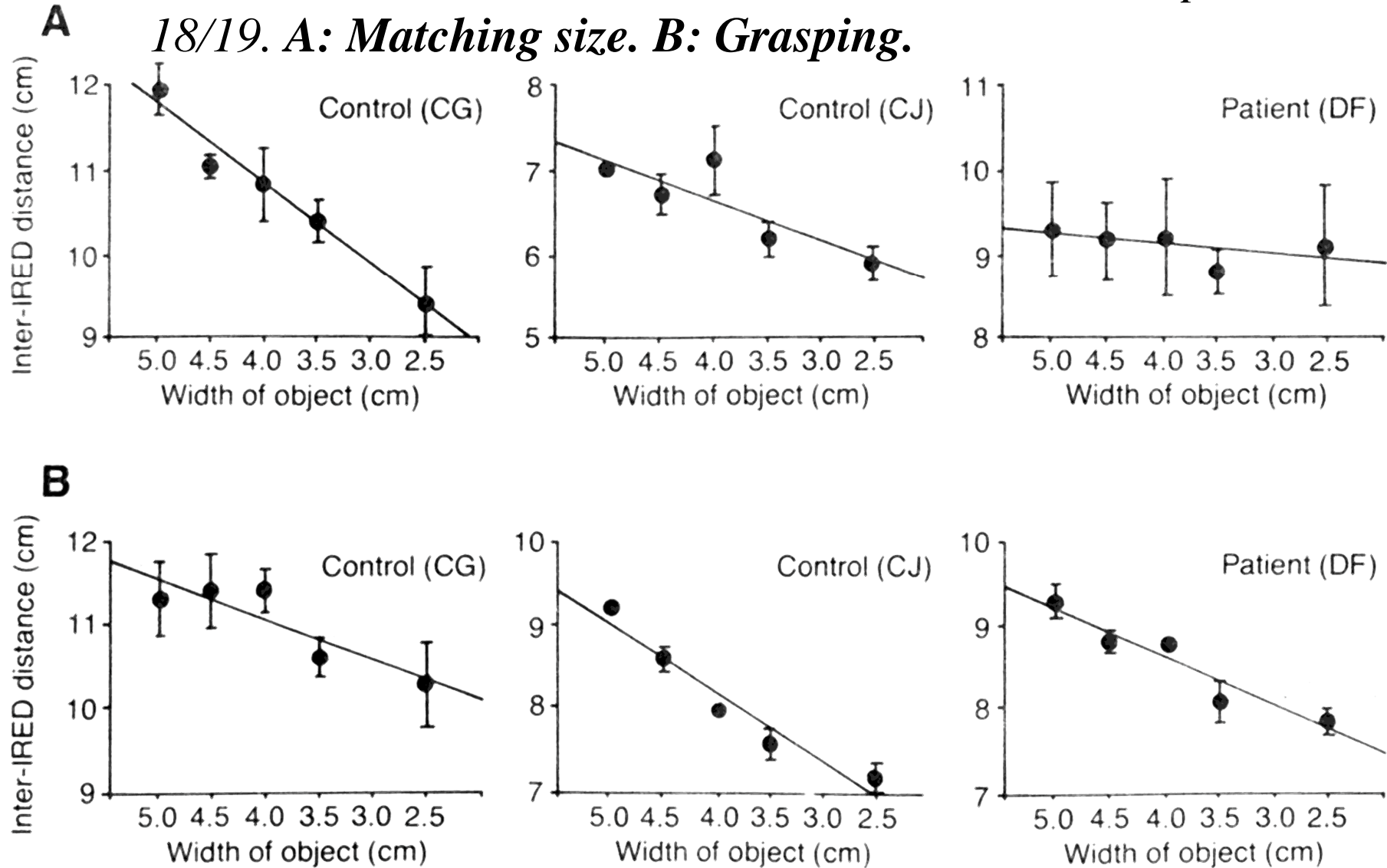


*Milner (1998)*



# Impaired perception of object size, but normal actions

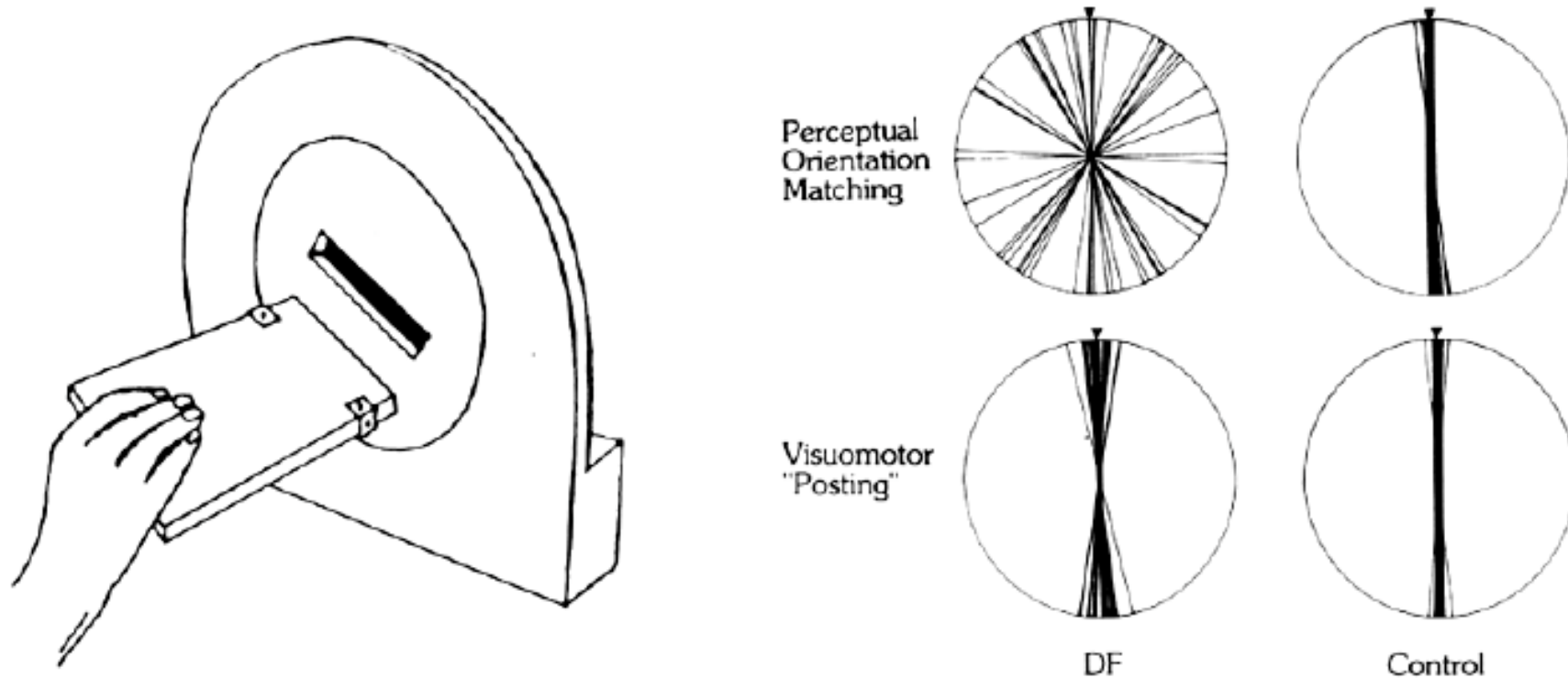
*Patient D.F.; ventral stream lesion due to anoxia; esp. areas 18/19. A: Matching size. B: Grasping.*



# Impaired perception of orientation, but normal actions


---

*Patient D.F.; ventral stream lesion (due to anoxia secondary to carbon monoxide poisoning); esp. areas 18/19*



# Object constancy in the ventral stream (1 - shadow)

---



*Weiskrantz & Saunders (1984) - impaired by TE (inferotemporal) lesions, not parietal lesions*

# Object constancy in the ventral stream (2 - size, orientation)

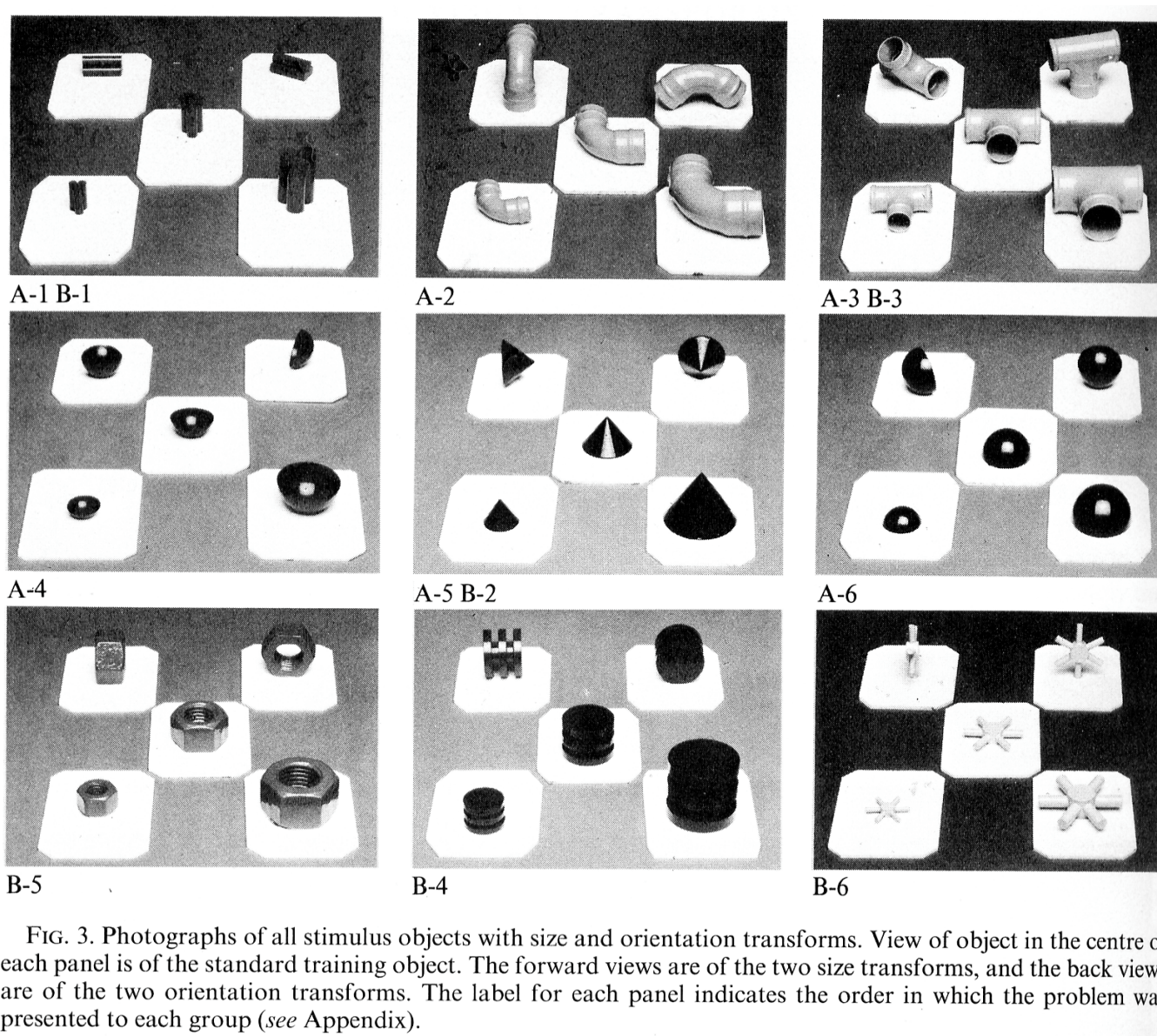


FIG. 3. Photographs of all stimulus objects with size and orientation transforms. View of object in the centre of each panel is of the standard training object. The forward views are of the two size transforms, and the back views are of the two orientation transforms. The label for each panel indicates the order in which the problem was presented to each group (see Appendix).

*Weiskrantz & Saunders (1984) - impaired by TE (inferotemporal) lesions, not parietal lesions*

## Summary

---

- **Ventral stream is *object-centred*.** Object detection largely irrespective of position, sometimes independent of viewpoint, etc. Required for visual awareness?
- **Dorsal stream is *visuomotor*.** High spatial precision for guidance of action. Unconscious?
- The **posterior parietal cortex maintains multiple maps of space** with which it can control actions; some approximate allocentric maps (independent of eye/body position to a degree).
- The **posterior parietal cortex has *attentional* functions**, separate from its visuomotor functions. To be continued...

